RESEARCH ARTICLE

The Ongoing Challenge of Achieving Precise Diagnosis of Fetal Chromosome Disorders by FISH in Autopsies

Mercedes Olaya-C[1], Olga M Moreno[2]

Received on: 11 February 2022; *Accepted on:* 15 February 2023; *Published on:* 12 May 2023

Abstract

Introduction: Chromosome abnormalities are an important cause of fetal and perinatal deaths. Molecular testing can be a useful tool in preconception counseling in selected families. However, such testing is neither routine nor mandatory at many healthcare centers; a number of factors can contribute to the lack of genetic and chromosome diagnoses.

Materials and methods: We performed an observational analytical study on 42 paraffin-embedded samples from fetal autopsy tissue with the suspected chromosomal disorder; we tested the efficacy of the fluorescence *in situ* hybridization (FISH) probe to ascertain the presence of common chromosome abnormalities.

Results: Use of the FISH technique in paraffin-embedded tissue has been standard practice in oncopathology; there now exists standardization of these probes in fetal and neonatal tissue. Our study analyzes various difficulties we encountered with the FISH probe when used for chromosome abnormalities diagnoses in fetal autopsies, and we conclude with pertinent recommendations for improving test outcomes.

Conclusion: Simultaneous occurrence of chromosome disorders and advanced maceration is common; maceration interferes with the proper performance of the FISH test; however, we view this diagnostic tool as appropriately functional when used under specific conditions.

Keywords: Abortion, Anatomic pathology, Birth defects, Fetal diseases, Fluorescence *in situ* hybridization, Neonatal–perinatal medicine, Spontaneous.

International Journal of Infertility and Fetal Medicine (2023): 10.5005/jp-journals-10016-1311

Introduction

Perinatal deaths are a public health issue of major concern; therefore, one of the objectives of fetal and neonatal autopsies is to determine the cause of death. In the prenatal age-group, especially among the youngest (fetuses and embryos), chromosome disorders are frequently identified as the etiology attributable to early death. Despite this fact, molecular testing does not make up part of daily routine procedures in our local pathology laboratories.[1] Diagnoses most likely rely on the use of an indiciary paradigm based on oftentimes very subtle macroscopic fetal morphological findings. When the simultaneous study of the placenta is also possible, abnormal morphological findings in the villi linked to chromosome disorders can aid in determining diagnoses.[2] The aim of our study was to test the efficacy of FISH probes in paraffin-embedded tissue samples in order to identify the most commonly occurring chromosome abnormalities; to do so, we selected patients who had undergone perinatal autopsy with presumptive diagnoses of possible chromosome disorders based on anatomical pathology. Once we had tested the method and selected target genetic abnormalities, we attempted to explain the use of FISH probes in our perinatal autopsy reports so that physicians and expectant parents could better understand the aim of genetic counseling.

Materials and Methods

Patient Selection

We identified 42 presumptive chromosome disorder cases from the years 2012–2013 archived in the fetal and perinatal mortality database of the Pontificia Javeriana University-San Ignacio Hospital, Bogota, Colombia, pathology department. All archive autopsy accounts recorded natural deaths and included necropsy consent that extended to the use of data and samples for future research studies. The Institutional Research and Ethics Committee of the Faculty of Medicine, Pontificia Universidad Javeriana-Hospital Universitario San Ignacio, Bogota, Colombia, approved our genetic research proposal that included the proposition to contact patients' family members once the study's final report became available, with the option of receiving additional information in consultation with a medical geneticist.

Following the selection of diagnosed cases of possible chromosome abnormalities, and before initiating FISH probes, we assigned, whenever possible, each case to a group according to its suspected morphological abnormalities type—the most probable

[1]Department of Pathology, Hospital Universitario San Ignacio; Department of Pathology, Institute of Human Genetics, Pontificia Universidad Javeriana, Bogota DC, Colombia

[2]Institute of Human Genetics, Pontificia Universidad Javeriana, Bogota DC, Colombia

Corresponding Author: Mercedes Olaya-C, Department of Pathology, Hospital Universitario San Ignacio; Department of Pathology, Institute of Human Genetics, Pontificia Universidad Javeriana, Bogota DC, Colombia, Phone: +57 6015946161, e-mail: olaya.m@javeriana.edu.co

How to cite this article: Olaya-C M, Moreno OM. The Ongoing Challenge of Achieving Precise Diagnosis of Fetal Chromosome Disorders by FISH in Autopsies. Int J Infertil Fetal Med 2023;14(2):70–74.

Source of support: Nil

Conflict of interest: None

© The Author(s). 2023 Open Access This article is distributed under the terms of the Creative Commons Attribution 4.0 International License (https://creativecommons.org/licenses/by-nc/4.0/), which permits unrestricted use, distribution, and non-commercial reproduction in any medium, provided you give appropriate credit to the original author(s) and the source, provide a link to the Creative Commons license, and indicate if changes were made. The Creative Commons Public Domain Dedication waiver (http://creativecommons.org/publicdomain/zero/1.0/) applies to the data made available in this article, unless otherwise stated.

being chromosomal trisomies 21, 13, and 18, and monosomy X. In order to unify FISH probes, we arbitrarily chose the kidney as the only target organ from which to select paraffin-embedded sections.

FISH in Paraffin-embedded Tissue

For slide preparation, we cut 5 µm wide sections from paraffin blocked tissue samples, dewaxed them with xylol, then immersed them in 100, 80, and 70% ethanol, and in pretreatment Aquarius® Tissue Pretreatment Kit (Cytocell) solutions at 100°C for 34 minutes and, finally, treated with pepsin at room temperature for 30 minutes. We then dehydrated liberated cells from the extracellular matrix in 70, 90, and 100% ethanol solutions, made tissue contact with a probe and sealed slides with rubber solution glue (Cytocell). We denatured the probe and sample simultaneously on a heat plate at 75°C and incubated them for hybridization for 18 hours (overnight) at 37°C. In the next step, we treated slides with 0.4 × saline sodium citrate (SSC) pH 7.0 at 72°C for 2 minutes, followed by 2 × SSC solution with Tween 20 at 0.05% at room temperature for 30 seconds to eliminate excess probe. The final step consisted of DAPI (Cytocell) staining to allow for hybridization analysis under the microscope. We employed standard prenatal diagnostic Cytocell enumeration probes to identify fetal tissue aneuploidies through FISH in chromosomes 13 and 21 (unique sequences 13q14.2 and 21q22.13, respectively); for chromosome 18, we employed the alpha satellite probe D18Z1. Vysis probes [Chromosome enumeration probe (CEP) X SpectrumOrange/Y SpectrumGreen] identified sex chromosomes (DXZ1/DYZ1: Xp11.1-q11.1/Yq12). We analyzed cell samples with the aid of a fluorescent microscope equipped with FISH GenASIs V.7.2 FISH view software. We then counted all of the fluorescent signals in each nucleus probed, establishing a minimum of 200 nuclei per case in order to determine the presence of mosaicisms. The description of results complies with International System for Human Cytogenomic Nomenclature (ISCN 2020) guidelines.

Maternal contamination was not a risk because the tissues came from the bodies of the fetuses.

Results

Table 1 outlines the clinical characteristics of the population; prior publication of phenotype characteristics appeared elsewhere.[1] We delineated characteristics in order to optimize probe performance, aiming initial probes at "the most probable" in accordance with the patient´s phenotype.

Once we achieved standardized controls, we carried out scaled probes in tissue sections, testing each probe individually (13/21, 18, and X/Y); however, the order in which we tested each probe varied depending upon the clinical suspicion of each case.

Among the cases analyzed, we obtained adequate imaging and possible diagnosis in four cases (Figs 1C2, C8, C9, and C14). Several cases resulted in erroneous with probes appearing for only one probe; in four other cases (cases three, 10, 11, and 13), we were unable to evaluate the sample (Fig. 1C11). Nonevaluable cases emitted[1]—either no signals or multiple signals that, in turn, impeded defining whether they belonged to a unique nucleus or whether they were three abnormal signals, or just one, from a single nucleus,[2] nuclei were poorly defined,[3] signals were weak and diffuse over a wide background (Figs 1C5, C6, C12, C15 and C16).

During the evaluation process, we found that case quality did not meet expectations. Below, we describe some of the problems we encountered as follows:

Table 1: Demographic characteristics of a sample of fetuses resulting from abortion and perinatal death

Variable		*n (%)*
Gender	*F*	21 (50,0)
	M	18 (42,9)
	Not determinable	3 (7,1)
Maternal age (years)	*(median)*	31,5 (23–36)
	<18	1 (2,4)
	18–35	30 (71,4)
	>35	11 (26,2)
Gestational age (weeks)	*(median)*	15,5 (13,0–21,7)
	<24	32 (76,2)
	24–36	8 (19,0)
	37–40	2 (4,8)
	>40	0
Gestations	*1*	15 (35,7)
	2	8 (19,0)
	3	12 (28,6)
	4	3 (7,1)
	5	2 (4,8)
	>5	2 (4,8)

Nuclei

Concise circumscription for adequate signal reception was rarely present; instead, what did appear were diffuse signals, difficult to decipher due to widespread maceration (see below). These shortcomings also made it impossible to count the number of nuclei. Figure 1C1A and B illustrate the inadequacy of both the nuclear morphology and the genetic material, both of which exhibit signs of degradation.

Probe Size

The selected probes were too small (normally used in cultured tissue or on swabs of suspended cells fixed on a slide), thus making detection very difficult in the macerated tissue fields where morphology was not preserved. Figure 1C4C shows nuclei that have no central staining and illustrates the loss of genetic material, as well as inadequate recognition of probe-induced homologous sequencing (hybridization with probe X/Y).

Probe Intensity and Fluorescence

We initially acquired multiple probes with five color simultaneous identification that required infrequently used filters to capture color emissions and with which our fluorescent microscopes were not equipped. We then acquired a multi-probe kit with five different fluorescent colors for simultaneous hybridization of the five chromosomes; nonetheless, there were very few signals emitted and they were difficult to detect within the solid tissue.

Probe Multiplicity

We used multiple simultaneous probes, which complicated individual signal identification.

Deoxyribonucleic Acid (DNA)

This was a foreseeable difficulty—due to tissue fragmentation, genetic fetal material extracted from paraffin block tissue samples (Figs 1C1 and C8) turned out to be a less ideal source. These drawbacks, when added to those described above, probably

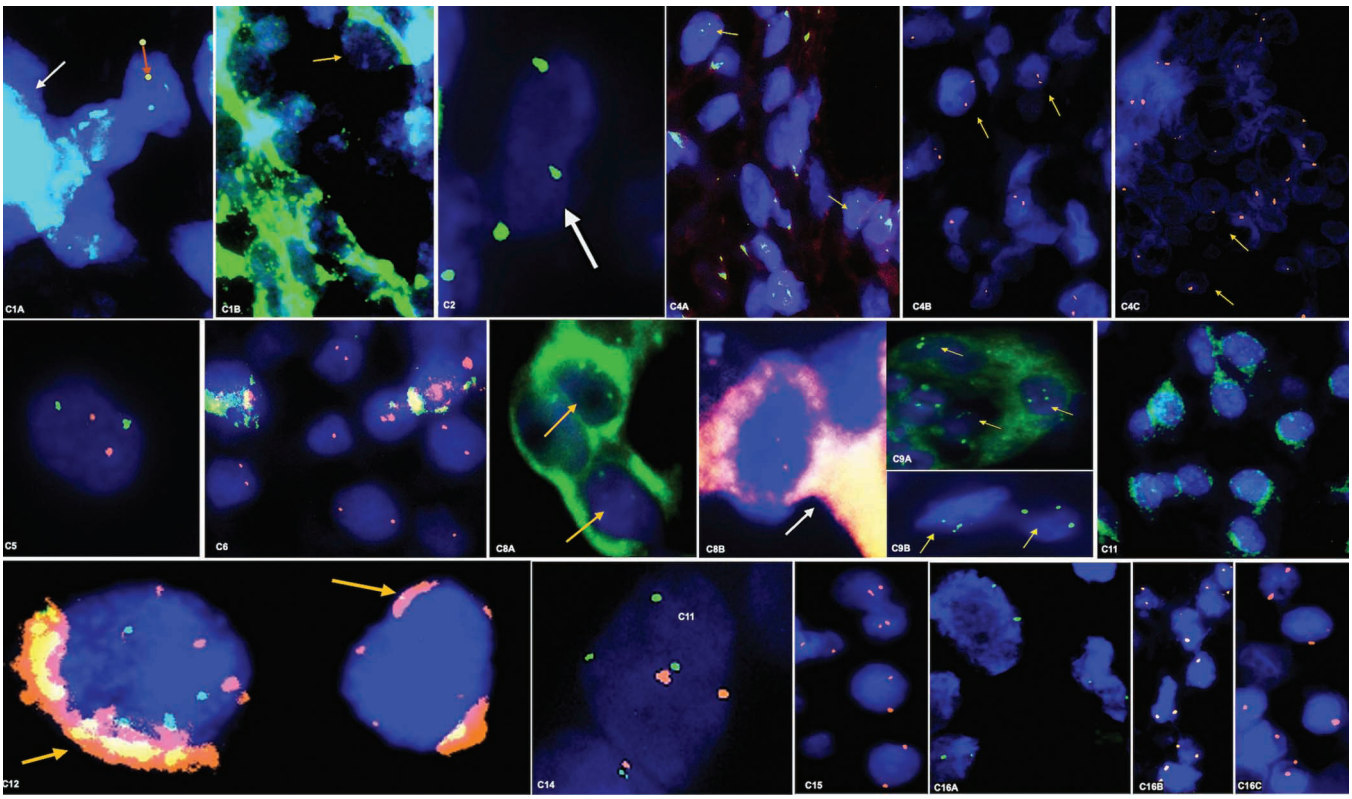

Fig. 1: FISH's images per case, its results and difficulties: (C1A) Probe for chromosome 18 recognition (orange arrow) (Cytocell 18 centromere 18p11.1-q11.1 (*D18Z1*) green). Paraffin presence (gray arrow); and (C1B) degradation of genetic material in nuclei (yellow arrow); (C2) Chromosome 18 probe—nucleus with three signals for chromosome 18 (gray arrow). Trisomy 18—nuc ish (D18Z1x3). Paraffin presence (yellow arrow); (C4A) Probe for chromosomes 13/21 recognition—in this slide, there was no hybridization of the probe for chromosome 21. Probe for the recognition of chromosome 13 (13q14.2) (green signals); (C4B) Probe for chromosome 21 recognition (21q22.13) (red signals); (C4C) X/Y probe (DXZ1/DYZ3) (red/green). Phantom nuclei and cannot be defined if it is monosomy or loss of the signal area; (C5) Probe for chromosome 13/21 recognition—there was no abnormality in the number of copies of chromosome 13 (green) or 21 (red). Nucleus with green and red signals that identify chromosomes 13 and 21, respectively; (C6) Probe for chromosomes 13/21 recognition. There were no abnormalities in chromosome 21 (red signals), there was no hybridization of the green probe that identifies chromosome 13; (C8A) D18Z1 probe—Trisomy 18—nuc ish (D18Z1x3). Although all three signals were observed for 18, high autofluorescence was also observed due to the presence of extracellular matrix and paraffin that overlaps with the signals that recognize the chromosome; (C8B) Probe for chromosome 21 recognition—autofluorescence similar to that described for probe 18 was observed (gray arrow); (C9A and C9B) Probe for chromosome 18 recognition—Trisomy 18—nuc ish (D18Z1x3); (C11) There was no hybridization. Nonspecific fluorescence; (C12) Probe for chromosomes 13/21 recognition (green/red)—single sequence probes 13q14.2/ 21q22.13. Presented paraffin traces that make autofluorescence analysis difficult (arrows); (C14) Probe for chromosomes 13/21 recognition (green/red)—single sequence probes 13q14.2/21q22.13. There are three signals greens identifying chromosome 13 and two red signals identifying chromosome 21—Trisomy 13—nuc ish (D13S917/ D13S153/ D13S1218x3); (C15) Alpha satellite probe for identification of chromosome X—nuc ish (DXZ1x2, DYZ3x0). Vysis CEP SpectrumOrange/SpectrumGreen probes; (C16A) X/Y probe. No abnormalities in X chromosome, nuc ish(DXZ1x2) red signals; (C16B) Probe for chromosome 21 recognition—single sequence probes (21q22.13) orange and no hybridization of the probe for chromosome 13; (C16C) Probe for chromosome 18 recognition—green signals, nuc ish (D18Z1x2)

hampered probe hybridization. In fact, several probes emitted no signals at all, in spite of the fact that we had modified tissue preparations and applied adequate positive controls.

Tissue Fixation

Some of the tissue samples we tested had likely reposed in formalin solution for up to 3 days while awaiting administrative authorizations following the autopsy. Consequently, the possibility was high that are samples contained poor quality deteriorated tissue, a factor that almost certainly deterred probe hybridization.

Tissue Buffer

In the course of our study, there were months when we did not use formalin as a tissue buffer, which undoubtedly affected tissue immune reactivity and DNA structures.

Mosaicism

The possible presence of placental mosaicism probably interfered with reaching a definitive diagnosis.[3]

Maternal Outcome

The likelihood that we might have analyzed maternal tissue, especially when probing the placenta, was always present. When accomplishing reactivity was impossible in some fetuses, we probed other organs (including the placenta).

Discussion

The predominant methods utilized to predict or encounter chromosomal and genetic abnormalities during the first trimesters of pregnancy have included nuchal translucency,

as well as measurements of pregnancy-associated plasma protein-A and human chorionic gonadotropin. During the second trimester, measurements of these levels include those for estradiol and, on occasion, for inhibin A.[4] Additionally, the presence of suspected chromosome abnormalities sometimes calls for the use of amniocentesis and karyotyping. The most common abnormalities (80% of all diagnosed prenatal abnormal chromosome cases) identified by fetal karyotyping involve trisomy 21 (Down syndrome), trisomy 18 (Edwards syndrome), trisomy 13 (Patau syndrome), 45,X (Turner syndrome), and 47,XXY (Klinefelter syndrome).[4,5] The use of FISH, multiplex ligation-dependent probe amplification (MLPA), and quantitative fluorescent polymerase chain reaction (PCR) have shortened the waiting period for the delivery of karyotyping results, thus putting them in increasing demand in developed countries.

In the fetal population, genetic and chromosome abnormality studies have relied on DNA extraction from direct or cultured chorionic villi,[6,7] direct amniotic liquid,[5,8] cultured amniotic cells, cultured umbilical cord blood,[9,10] and fetal tissue blood.[7,11] In cases of repetitive gestational failure, parental samples join the list of analyzed DNA sources.[12] Techniques for genetic analyses include conventional karyotyping, FISH, MLPA, chromosomal microarray analysis,[7,13] comparative genomic hybridization,[5,11,14] and genomic sequencing.[12]

These techniques usually require the extraction of fresh or cultured tissues from their respective sources, which, in turn, obliges the attendant medical team to take adequate samples from parents with a history of failed pregnancies;[15] and in other cases, to take fetal genetic samples after closely examining fetal ultrasound images that suggest the presence of fetal abnormalities.

In our local setting, we have witnessed an increase in requests for prenatal testing for genetic and chromosome abnormalities; however, such testing is not applicable to all cases. There are cases in which diagnosis of abnormality debuts at the time of fetal death; subsequently, macroscopic autopsy findings and microscopic placental findings create suspicion of genetic abnormalities. Because death occurs at an early stage in gestation, a delay of several days or weeks is common in determining cause of death diagnosis, which makes it impossible to extract fresh or viable tissue for culture. Hence, in determining chromosome abnormalities, we would like to make greater use of the increasingly popular FISH technique that relies on paraffin-embedded tissue, a now standard technique in various types of cancer cell analysis.

Pathologists often ground their findings contained in fetal death reports on FISH probes, which are capable of detecting the most common chromosome pathologies, even when maceration is present.[16] Furthermore, they can resort to the use of FISH probes to carry out conventional cytogenetic analysis or other types of karyotyping when cell extraction for lab culture is not possible.

Maceration is due to a combination of factors that appear in a usually aseptic liquid environment at 37°C prior to fetal death; this temperature favors enzyme liberation that causes autolysis that consequently leads to maceration. From the moment of intrauterine death, maceration undergoes constant changes that are visible in exterior and interior fetal examinations and in fetal organ and placental pathology analyses.[17] We compared cases in order to analyze the association between severe maceration and presumptive chromosome abnormalities diagnoses; when chromosome abnormalities were present, there was a greater risk of sudden death at any moment during the intrauterine life span. Death due to chromosome abnormalities usually occurs early in gestation; however, the prompt diagnosis does not always follow, thus permitting severe maceration to expand.

Figure 2 compares the histological aspects of organs with and without severe maceration. Haziness in aspect impedes proper morphological evaluation of cells, even if stained, and inhibits nuclear definition with FISH.

As mentioned above, the simultaneous occurrence of chromosome/gene disorders and advanced maceration interferes with the adequate implementation of the FISH probes; nevertheless, we view this diagnostic tool as appropriately functional when used under the following conditions:

- Lowered physician and family expectations—the probes do not always work.
- Probes designed for paraffin blocked tissues, whenever possible, or aimed at centromeric regions (α or β satellite sequences) to enhance visualization.
- Probes that emit different colored signals are clearly differentiated for the available filters.
- Well-preserved fetal tissue (short periods in formalin or buffered formalin) in cases with slight or no maceration. This helps to evaluate false mosaicism in maternal tissue.
- A preference for placental tissue over fetal tissue in cases of severe maceration.

Paraffin blocking of fetal tissues requires optimum quality control if FISH probes are to make up part of routine histological procedures.

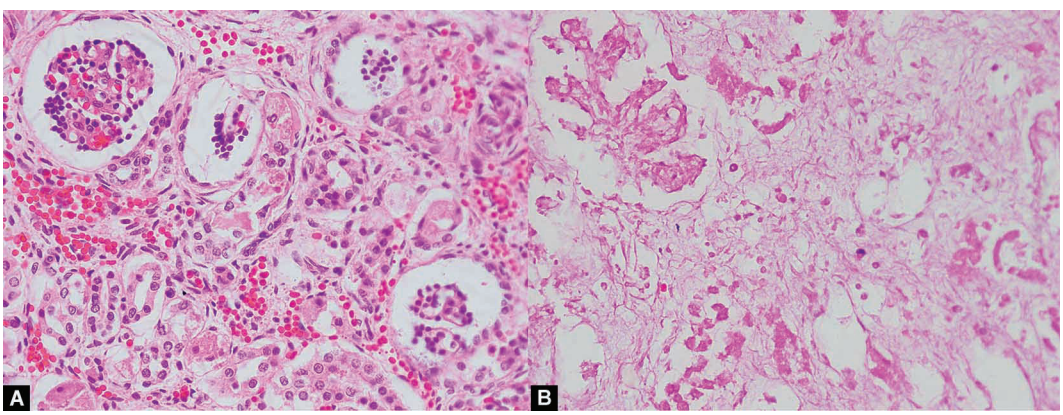

Figs 2A and B: Fetal kidneys. Slides stained with hematoxylin and eosin 40×: (A) Kidney not macerated. Note the well-defined nuclei as well as the cytoplasmic membranes. Glomeruli and tubules are adequately differentiable and components are recognizable; (B) Macerated kidney. Many nuclei have karyolysis (have disappeared) and cells are not precise. Glomeruli and tubules are ghostly with blurred contours

In our retrospective study, discussed herein, in which we carried out FISH probe analysis, it is probable that samples did not meet adequate fixing standards for such analysis because most showed signs of maceration. Our results allow us to suggest the use of other molecular methodologies, such as quantitative-PCR, to complement the genetic studies of fetal tissue that ensure the result for the family.

Acknowledgments

We wish to thank patients' families for consenting to this research project, as well as the San Ignacio Hospital of the Pontificia Javeriana University, Bogota, Colombia, for its support of perinatal pathology research. We also extend our thanks to Steven W Bayless for the translation from Spanish.

Statement of Ethics

All archive autopsy accounts recorded natural deaths and included necropsy consent that extended to the use of data and samples for future research studies. The Institutional Research and Ethics Committee of the Faculty of Medicine, Pontificia Universidad Javeriana-Hospital Universitario San Ignacio, Bogota, Colombia, approved our genetic research.

Funding Sources

This study constitutes part of the research project entitled, "Diagnosis of chromosomal disorders in fetal autopsy series at the Hospital Universitario San Ignacio" (ID PPTA 00006280), financed by the Pontificia Universidad Javeriana-Hospital Universitario San Ignacio in Bogota, Colombia.

Author Contributions

Olaya-C Mercedes—I declare that I participated in the study conception and design, acquisition of data and patients (case search), collection of clinical data, immunofluorescence review, the literature review and drafting of manuscript, and that I have seen and approved the final version.

Moreno Olga M—I declare that I participated in the study design, in the realization of the tests, in the review of molecular test results, collection of images, in the literature review and drafting of manuscript, and that I have seen and approved the final version.

Data Availability Statement

The authors declare that the data are available without unnecessary restriction.

Orcid

Mercedes Olaya-C https://orcid.org/0000-0002-7147-425X

References

1. Olaya-C M, Ortega RI, Suárez-Obando F, et al. Phenotypical characterization of patients who underwent perinatal autopsy at the Hospital Universitario San Ignacio. Univ Médica 2019;60(1):1–7. DOI: 10.11144/Javeriana.umed60-1.feno
2. Olaya CM, Zarante A. Trisomy 13 and its placental alterations. Univ Med 2012;53(4):443–451.
3. Khong TY. & MRD. Congenital Abnormalities: nosis and Screening. InPrenatal Diag:Khong TY.,Malcomson RD, editors. Keeling's Fetal and Neonatal Pathology. Fourth. Philadelphia: Springer; 2015. p. 123–61.
4. Elsayed GM, El Assiouty L, El Sobky ES. The importance of rapid aneuploidy screening and prenatal diagnosis in the detection of numerical chromosomal abnormalities. Springerplus 2013;2:490. DOI: 10.1186/2193-1801-2-490
5. Weise A, Liehr T. Rapid prenatal aneuploidy screening by fluorescence in situ hybridization (FISH). Methods Mol Biol 2008;444:39–47. DOI: 10.1007/978-1-59745-066-9_3
6. Poaty H, Pelluard F, André G, et al. Truncus arteriosus communis: report of three cases and review of literature. Afr Health Sci 2018;18(1):147–156. DOI: 10.4314/ahs.v18i1.19
7. Lovrecic L, Remec ZI, Volk M, et al. Clinical utility of array comparative genomic hybridization in prenatal setting. BMC Med Genet 2016;17(1):81. DOI: 10.1186/s12881-016-0345-8
8. Su SY, Chueh HY, Li CP, et al. Interphase fluorescence in situ hybridization assisting in prenatal counseling for amniocentesis karyotyping-detected fetal mosaicism. Taiwan J Obstet Gynecol 2015;54(5):588–591. DOI: 10.1016/j.tjog.2015.08.019
9. Sheth F, Rahman M, Liehr T, et al. Prenatal screening of cytogenetic anomalies-a Western Indian experience. BMC Pregnancy Childbirth 2015;15:90. DOI: 10.1186/s12884-015-0519-y
10. Chakravarty A, De P, Chakravarty S. Invasive pre- and postnatal genetic evaluation reduces the reproductive risk in the era of noninvasive or minimally invasive prenatal screening method. Int J Gynecol Endosc 2017;1(1):35–39. DOI: 10.5005/jp-journals-10058-0008
11. Yakut S, Çetin Z, Şimşek M, et al. Prenatal tanıda nadir yapısal kromozom anomaliler; 10125 prenatal olgunun klinik ve sitogenetik bulguları. Turk Patoloji Derg 2015;31(1):36–44. DOI: 10.5146/tjpath.2014.01280
12. Dong Z, Yan J, Xu F, et al. Genome sequencing explores complexity of chromosomal abnormalities in recurrent miscarriage. Am J Hum Genet 2019;105(6):1102–1111. DOI: 10.1016/j.ajhg.2019.10.003
13. Tidrenczel Z, Tardy EP, Pikó H, et al. Prenatal diagnosis of 4q terminal deletion and review of the literature. Cytogenet Genome Res 2019;158(2):63–73. DOI: 10.1159/000500735
14. Brun S, Pennamen P, Mattuizzi A, et al. Interest of chromosomal microarray analysis in the prenatal diagnosis of fetal intrauterine growth restriction. Prenat Diagn 2018;38(13):1111–1119. DOI: 10.1002/pd.5372
15. De P, Chakravarty S, Chakravarty A. Pre- and postnatal genetic evaluation reduce the reproductive risk of nonhomologous Robertsonian translocation carrier couple. Int J Infertil Fetal Med 2017;8(1):36–40. DOI: 10.5005/jp-journals-10016-1145
16. Jarzembowski JH DA. Molecular techniques in Pediatric Pathology. In:Stocker J DLHA, editor. Pediatric Pathology. Fourth. Philadelphia: Lippincott Williams and Wilkins; 2015. p. 21–46.
17. Olaya-C M, Galvis Navarrete SH, Giraldo Ospina GA, et al. Enfoque de las gestaciones múltiples de diagnóstico difícil durante la autopsia perinatal. Rev Ciencias la Salud 2017;15(3):357–371. DOI: 10.12804/revistas.urosario.edu.co/revsalud/a.6120